Skin, Soft Tissue, & Bone Infections

G. Volpe, MD
November 9, 2011
Milot, Haiti

Skin & Soft Tissue Layers

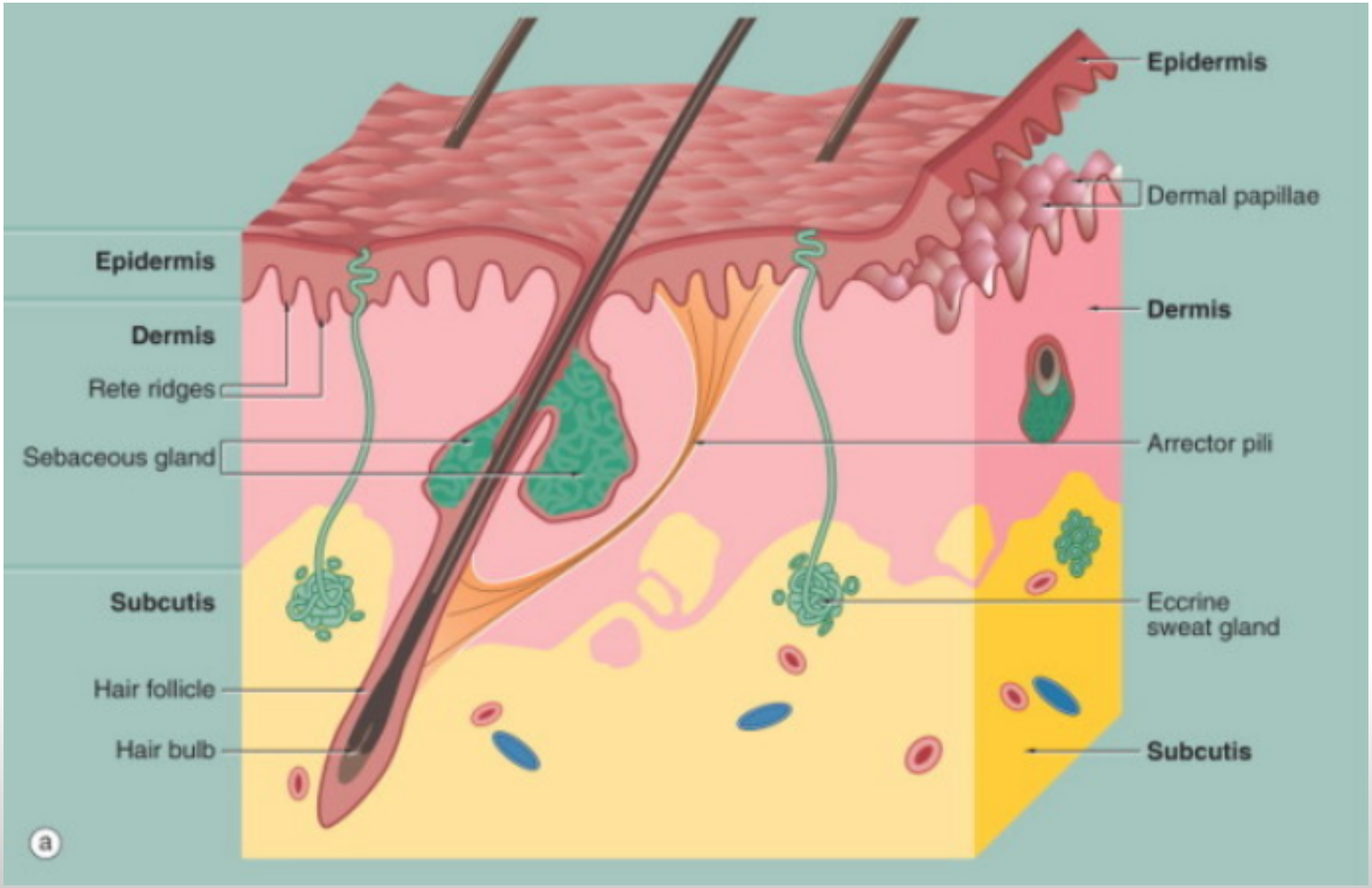

Cellulitis

- Definition: inflammation of dermal and subcutaneous tissues due to nonsuppurative bacterial invasion

- Likely risk factors:
  - trauma, peripheral edema, tinea pedis, skin break, deep abscess

- Pyogenic, bacterial infection:
  - Group A Streptococcus: fatty acid layer of skin is major barrier to spread of streptococci so red streaking of lymphangitis is seen with streptococci rather than abscess as seen with staphylococcus
  - Staph aureus
  - H.influenza and Strep pneumoniae (children)
  - Vibrio vulnificus: liver disease, salt water or raw seafood; hemorrhagic bullae, lymphadenitis, myositis, disseminated intravascular coagulation [DIC], septic shock
  - Gram negative bacilli: infants, diabetes, immunosuppressed
  - Pasteurella multocida: cat and dog bites

Erysipelas

- Erysipelas is a superficial cellulitis of skin and subcutaneous tissues with a sharply demarcated firm raised border caused by group A Streptococcus (or Staph if facial)

Facial Erysipelas

Symptoms and Signs

- Red, warm, swollen, tender area of skin
- Poorly demarcated margins
- Lower legs are most common location
- May not find breaks in skin
- May find dimpling around hair follicles: "peau d'orange"
- Other finding: vesicles or bullae filled with clear fluid, petechiae, ecchymoses

- Occasionally mild systemic symptoms: fever, confusion, hypotension, regional lymph nodes
- Elevated wbc

Treatment

- Elevation
- Oral antibiotics, such as dicloxacillin

- For more severe cases or diabetic foot ulcers, use IV antibiotics effective against *Staphylococcus* and *Streptococcus*
- For dog, cat, or human bite, consider amoxicillin-clavulanate

- For fresh water lacerations, consider ciprofloxacin 400 mg IV every 12 hours
- For salt water laceration consider doxycycline 200 mg IV initially, followed by 100-200 mg IV daily in 2 divided doses in conjunction with targeted antimicrobial therapy

Abscesses

- Definition: collection of pus within dermis and deeper skin tissues due to infection
- Usually polymicrobial, with normal regional skin flora/mucous membranes
- S. aureus (25%)

- Risk factors:
  - obesity
  - diabetes
  - atopic dermatitis
  - chronic kidney disease
  - malnutrition
  - immune suppression/corticosteroids
  - IV drug use
  - close contact with others with furuncles, e.g. sports teams
  - hygiene

- Treatment: Incision and drainage, dry sterile dressings; antibiotics only if extensive cellulitis or fever (systemic signs)

Necrotizing Fasciitis

- Deep soft tissue infection, rapidly progressive bacterial infection
- Fournier's gangrene - necrotizing infection of perineum and scrotum
- Streptococcus pyogenes, mixed anaerobes, gram-negative rods
- Entry with surgery, minor trauma (small puncture wound) or any open trauma; progression over minutes-days; causes vascular thrombosis
- Likely risk factors: surgery, ruptured viscus, DM, children with varicella infection

Signs & Symptoms

- Pain out of proportion to exam finding
- Signs of progressive toxicity (fever, tachycardia); less commonly localized wound pain, foul serous discharge

- **Skin:**
- minimal cutaneous signs
- overlying skin may appear normal; hemorrhagic bullae, edema, redness, crepitus

Treatment

- High mortality
- Clindamycin, aminoglycoside, penicillin G, penicillinase-resistant penicillin if staph
- radical extensive debridement immediately and repeated within 12-24 hours
- remove all infected or devitalized tissue at first debridement
- daily debridement may be necessary

Case I

26F with obesity presents with a large, 5cm abscess on her inner right thigh. The abscess is painful but she denies any other symptoms.

On exam, she is afebrile, BP 125/80, and no signs of systemic illness. The abscess is tense, fluctuant, and with a small rim of surrounding erythema.

What is the first step in management?

Case I: Answer

Incision and drainage of abscess using sterile techinque.

Gram stain of the fluid could be helpful.

Antibiotics are indicated if extensive cellulitis or systemic signs such as fever.

Case II

58M with chronic edema of his left leg develops a low grade fever and a confluent red rash across the lower third of his leg below the knee.

On exam there is pain, warmth, and erythema of the skin of the lower left leg, with poorly demarcated margins and several bullae filled with clear fluid. There is tinea pedis in the spaces between the toes of the feet bilaterally.

In addition to antibiotics, what other steps would be helpful in treating and preventing this infection?

Case II: Answer

-Leg elevation
-Treatment of tinea pedis with appropriate foot care

Case III

53M has sudden onset of left calf pain. Within hours, skin and subcutaneous tissues are red, edematous, and tender. Red streaks are seen spreading proximally.

A short time later, he is brought to the hospital with confusion and hypotension. Temperature is 40 degrees Celsius, with diffuse erythema of the skin. He is tachypneic. His wbc is 3000 with 25% polys and 50% bands.

Which therapy would you suggest?

Case III: Answer

Ceftriaxone and clindamycin.

This is toxic shock syndrome, likely secondary to streptococcus. This involves invasive disease AND toxin production, leading to hypotension, renal failure, DIC, liver injury and acute respiratory distress.

With Staph aureus toxic shock, there is no invasive disease, but only a colonized site.

Clindamycin inhibits the toxin.

Case IV

37M with alcoholism spent the day at the beach and cut his right great toe on some shells. He presents several hours later with hypotension and painful cellulitis, with large blood-filled bullae.

What organisms would you be concerned about and how would you treat him?

Case IV: Answer

Vibrio vulnificus.

Treat with Ceftriaxone and doxycycline.

This organism is often resistant to aminoglycosides.

Case V

69F with multiple myeloma on chemotherapy presents with pain and redness at her outer right thigh.

On exam, the patient is very uncomfortable and somewhat confused. Her BP is 85/40, P 110, Temp 39 degrees Celsius. Her right thigh has some mild, poorly demarcated erythema and it is exquisitely painful to touch. There is some mild edema of the tissues underneath the skin.

What infection would you be most worried about in this patient?

Case V: Answer

Necrotizing fasciitis.

Systemic signs and symptoms are present and local symptoms are mild. Pain at local site is greater than would be expected given the other physical findings.

Consult surgery immediately.

Diabetic Foot Ulcer

- Causes: neuropathy, pressure, ischemia, or venous hypertension

Infectious Diseases Society of America (IDSA) clinical classification of diabetic foot infection

- Uninfected: wound without purulence or any evidence of inflammation
- Mild infection: limited to skin or superficial subcutaneous tissue with ≥ 2 signs of inflammation (purulence, or erythema, pain, tenderness, warmth, or induration); limited to ≤ 2 cm around wound; no other local complications or systemic illness
- Moderate infection: involving muscle, tendon, bone, or joint with ≥ 2 signs of inflammation or cellulitis > 2 cm around wound; clinically stable
- Severe infection: systemic toxicity or metabolic instability (such as fever, chills, tachycardia, hypotension, confusion, vomiting, leukocytosis, acidosis, severe hyperglycemia, or azotemia)

Diabetic Foot Ulcer, continued...

- Other risk factors:
  - repetitive trauma from pressure on plantar bony prominences (usually metatarsal heads)
  - foreign bodies in footwear
  - poorly fitting footwear
  - puncture wounds
  - tinea pedis/onychomycosis
  - prior ulcer, prior surgery
  - peripheral vascular disease
- Most commonly isolated pathogens:
  - *Staphylococcus aureus*
  - beta-hemolytic streptococci (groups A, C, G and especially group B)
  - chronic wounds develop more complex colonizing flora usually polymicrobial, including various *Enterobacteriaceae, Pseudomonas aeruginosa,* enterococci, and obligate anaerobes

- Complications: osteomyelitis, sepsis, amputation

Features & Diagnosis

- Special features of diabetic ulcers

- Neuropathic ulcers: usually found under metatarsal heads or on plantar aspects of toes; warm extremity
- Ischemic ulcers: typically on medial and lateral aspects of feet as well as on toes; cool, pulseless foot
- Predictors of high pressure: callus, blister or macerated skin, limited hallux dorsiflexion (< 30 degrees), prominent metatarsal heads with minimal soft-tissue covering
- other plantar bony prominences
- Diagnosis:
  - purulent secretions OR
  - ≥ 2 signs of inflammation: redness, warmth, swelling or induration, pain or tenderness

- **Use of sterile steel probe in diabetic foot ulcers is simple test to detect osteomyelitis but can not rule out osteomyelitis**

Treatment

- General Measures:
  - Good glycemic control
  - Smoking cessation
  - Proper footwear
  - Off-load pressure, e.g. total contact cast
  - Moist wound environment
  - Daily inspection
- Mild to Moderate Infection:
  - narrow spectrum antibiotics to cover aerobic gram-positive cocci
  - 1-2 weeks, but occasionally 2-4 weeks required
- Severe Infection:
  - broad spectrum antibiotics, intravenous, for at least 2-4 weeks
  - consult surgery, podiatry, vascular surgery
  - urgent surgical consult for life- or limb-threatening infections
  - debridement, limited resections, and amputations may reduce need for more extensive amputations
  - Achilles tendon lengthening reduces recurrence rates for diabetic foot ulcer

Bone Structure

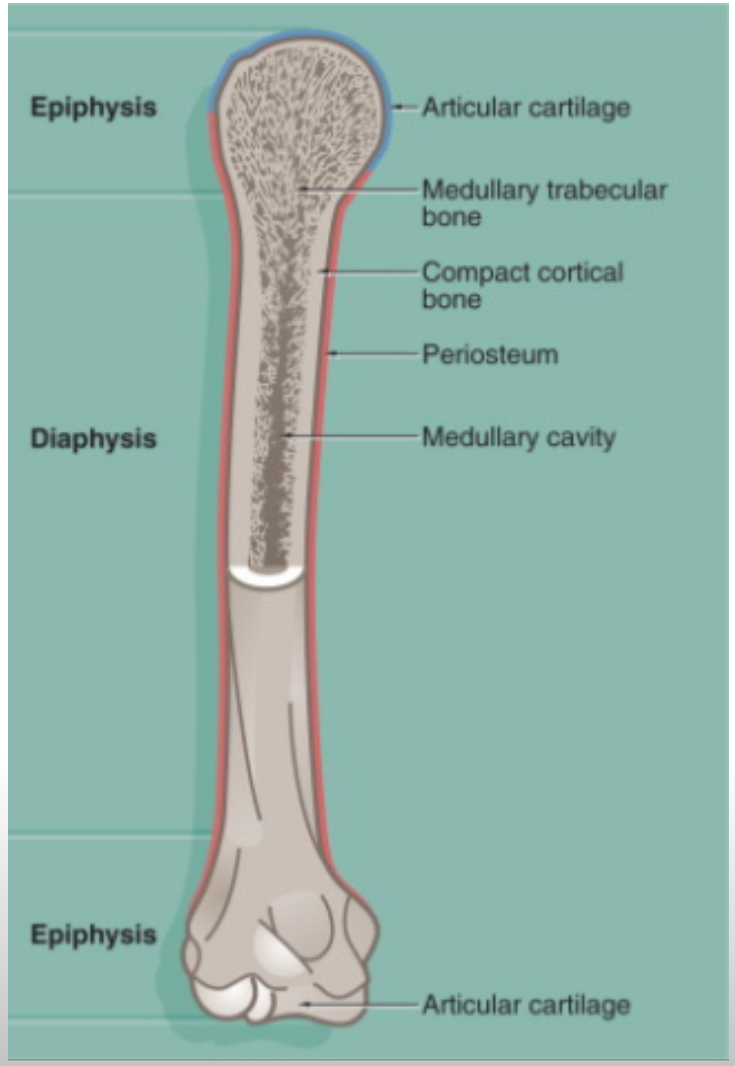

Osteomyelitis

- Definition: infection of bone that can lead to progressive destruction of bone
- Routes of Infection
  - Hematogenous: endocarditis, skin/soft tissue, IVs, etc.
  - Contiguous: adjacent focus, prosthesis, ulcer
  - Direct inoculation: puncture wound, surgery
- Risk factors
  - Malnutrition, age, renal/liver failure, DM, hypoxia, malignancy, immunosuppression, IV drug use, trauma/surgery, sickle cell disease
  - Lymphedema, vascular disease, scarring, neuropathy, tobacco
- Complications
  - Abscess (vertebral): epidural, psoas, retroperitoneal, mediastinal
  - Bone necrosis
  - Fistula
- relapse rate reported to be up to 20%
- inadequate debridement one cause of high recurrence rates
- **31% recurrence rate of osteomyelitis, most within 1 year**

Osteomyelitis

- *Staphylococcus aureus* is most common causative microorganism

- Hematogenous osteomyelitis is usually **monomicrobial**, e.g. UTI - aerobic gram-negative bacilli, enterococcus species
- Osteomyelitis from contiguous foci, e.g. DM, vascular insufficiency, contaminated fracture: **polymicrobial**

- Neonates: Enterobacteriaceae, Group B Strep, Staphylococci
- Infants and children: *H. influenza*
- Sickle cell: *Salmonella*, *S. pneumoniae*, anaerobes
- IVDU: *P. aeruginosa, Candida species (vertebral: S. aureus)*
- HIV: *Bartonella* species

Osteomyelitis Organisms, continued

- In endemic regions: *Mycobacterium tuberculosis*, *Brucella* species

- Post surgical, foreign body, or traumatic:
  - Orthopedic implants: *S. aureus*, coagulase-negative staphylococci
  - Spine surgery: coagulase-negative staphylococci, *S. aureus,* aerobic gram-negative bacilli
  - Puncture injuries: pseudomonas
  - Periodontal: actinomyces
  - Intravascular devices: *Candida* species
  - Soil contamination: Clostridium species, *Bacillus* species,
  - *Stenotrophomonas maltophilia, Nocardia* species, atypical
  - mycobacteria, molds
  - Human/animal bites: *Pasteurella multocida* (cat bite), *Eikenella*
  - *corrodens* or other anaerobic bacteria

Signs & Symptoms

- Pain, fever, local inflammation, sepsis
- Poor wound healing, fistula, wound infection
- Tenderness, limited motion, ulcer that probes to bone
- ↑WBC
- ↑ESR (>70mm/h) and CRP
- XRAY: changes may not be obvious until 5-7 days in children and 10-14 days in adults (chronic)
- significant changes on x-ray usually seen once osteomyelitis extends ≥ 1 cm and compromises 30%-50% of bone mineral content
- normal on admission in cases of vertebral osteomyelitis, neither sensitive or specific

Treatment

- Surgical debridement, with antibiotics, usually required for long-bone osteomyelitis, open fracture osteomyelitis, foot osteomyelitis, and early postoperative hardware-associated spine infection
- Duration of antibiotics usually > 4-6 weeks
- Mixed infection (aerobic and anaerobic organisms) treatment of choice - ampicillin-sulbactam 2-3 g IV every 6-8 hours
- Open-fracture osteomyelitis: chronic oral antimicrobial suppression until bone fusion may be useful if foreign bodies retained
- Treatment depends on suspected mode of infection, and suspected microbial agents (with gram stain)
- Vertebral osteomyelitis may need to be treated longer if complications

Osteomyelitis of toe with soft tissue edema

Septic Arthritis

- Definition: purulent infection in joint
- 80%-85% single large joints
- axial skeletal involvement mainly in IV drug users (MRSA, pseudomonas)
- Causes: S. aureus, Streptococcus, N. gonorrhoeae, gram negatives (elderly)
- Routes: hematogenous, direct inoculation
- Risk factors: joint surgery, skin infection + prosthesis, sickle cell disease
- Possible risk factors: ulcers, DM, alcoholism, IVDU, joint disease, HIV

Signs & Symptoms

- Joint pain, tenderness, warmth, restricted motion
- Fever, sweats, rigors
- ↑WBC, ESR, CRP
- Arthrocentesis: cell count and differential
- obtain specimen for Gram stain and culture prior to starting antibiotics
- polarizing microscopy to rule out crystal arthritis
- x-ray cannot diagnose septic arthritis but may be useful as baseline assessment of joint damage
- elevated white blood cell count > 50,000 cells/mcL suggestive of septic arthritis, but cannot rule out crystal arthritis

Septic Arthritis

- 11% mortality rate; higher with older age

- Treatment:
  - Aspirate joint to dryness as often as needed
  - Begin empiric treatment with IV antibiotics as soon as possible after gram stain
  - For patients without risk factors for resistant or atypical organisms: Ceftriaxone 1-2g IV q12-24 hours
  - For specific organisms suspected:
    - Gram negatives: 2nd or 3rd generation cephalosporin
    - Methicillin-resistant Staph aureus: vancomycin plus 2nd or 3rd generation cephalosporin
    - Gonococcus/Meningococcus: ceftriaxone
  - Guide choices based on local prevalence of organisms and resistance patterns
  - Duration of antibiotics: 2 weeks IV followed by 4 weeks of oral antibiotics, depending on resolution of symptoms and normalization of inflammatory markers (sedimentation rate and c-reactive protein)
  - May need longer for Staph aureus and gram negative bacilli

Case VI

80M with DM, with right knee replacement 3 months ago presents with constant pain and swelling in the right knee.

On exam, he is afebrile, with normal vital signs. His right knee is painful, swollen, and there is decreased range of motion.

What is the best test for establishing that this patient has a prosthetic joint infection?

Case VI: Answer

Aspirate and gram stain of joint fluid.

Case VII

21F injection drug user presents with fever and right sided chest pain.

On exam, febrile to 39 degrees Celsius, with 2/6 systolic murmur and swelling and tenderness over the right sternoclavicular joint.

Aspiration of the joint reveals a small amount of purulent material.

What syndrome would you be worried about?

Case VII: Answer

Infective endocarditis with seeding to sternoclavicular joint causing septic arthritis.

Systemic antibiotics should be given to cover gram positive organisms as well as gram negative organisms, specifically pseudomonas.

Case VIII

16M steps on a nail which punctures his sneaker and enters his heel. He sees a physician who gives him a tetanus booster and prescribes a 5 day course of amoxicillin/clavulanic acid.

Three weeks later, he has pain and purulent drainage from his right heel.

On exam, temperature is 38.2 degrees Celsius, and he has purulent drainage from sinus track of right heel.

What organisms would you like to treat for?

Case VIII: Answer

Gram positives (including MRSA)
Gram negatives
Pseudomonas (puncture through sole of shoe)

Case IX - Part I

A 65F with DM presents with an ulcer on the plantar surface of her left foot that is painful, red and swollen.

On exam she is afebrile and well appearing. The erythema around the ulcer is 1.5cm in diameter. There is a scant amount of purulence coming from the 0.8cm ulcer.

Is the ulcer infected?

Case IX - Part I: Answer

The ulcer is associated with four signs of infection/inflammation - erythema, edema, purulence and pain.

The surrounding cellulitis is <2cm, so the infection would be considered mild.

This would require 1-2 weeks of antibiotics to cover aerobic gram positive cocci.

Case IX - Part II

Upon further inspection, you notice that the ulcer looks very deep, and you are concerned about involvement of the underlying bone.

What test, that if positive, would make osteomyelitis very likely in this patient?

Case IX- Part II: Answer

The probe to bone test. If you can touch the bone through the ulcer with a sterile steel probe, then there is likely to be osteomyelitis.

Unfortunately, a negative probe to bone test does not rule out osteomyelitis.

Questions

Question 1

Do all cat bites need to be treated with antibiotics?

Answer 1

Yes.

Treat with amoxicillin/clavulanate or doxycycline. Both Eikenella and Pasturella are resistant to clindamycin.

Question 2

Erisypelas on the face could be due to what two groups of organisms?

Answer 2

Streptococci or staphylococci

Question 3

True or false: Necrotizing fasciitis can be treated by antibiotics alone.

Answer 3

False: necrotizing fasciitis requires emergent surgical debridement.

Question 4

What particular organism would you be concerned about for osteomyelitis in a patient with:

-Sickle cell disease?

-IVDU?

Answer 4

Sickle cell disease: Salmonella (and Staph aureus)

IVDU: Pseudomonas (and Staph aureus)

Question 5

Are Xray changes seen in acute osteomyelitis?

Answer 5

No. Usually, xray changes are only seen when osteomyelitis is chronic; for example, after 7 days in children and 14 days in adults.